

# OCT Angiography

- now combined with **Swept Source** DRI OCT Triton

## The Ultimate Advanced Diagnostic Instrument - Evolved

OCT Angiography is a novel and non-invasive imaging technique to visualize the microvascular network

Now you can perform angiography any time you need to. The optional OCT Angiography module offers non-invasive observation of the microvascular structures reducing the need for conventional fluorescein angiography.

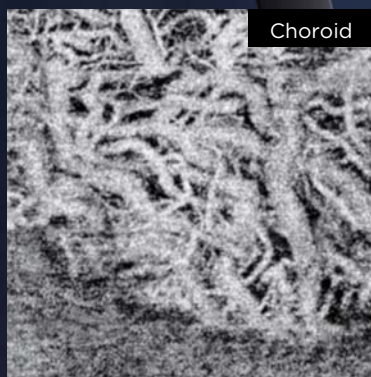- » By utilizing cutting-edge swept source technology with a wavelength of 1 micron, high-quality OCT Angiography images are acquired
- » Swept Source OCT's ultra-fast scan captures large quantities of data for excellent visualization
- » Easier recognition of abnormalities by using layer by layer "tissue peeling" intuitive graphical user interface
- » Improved patient's comfortably\*<sup>1</sup> - no dyes or dilation required, rapid capture
- » All-in-one powerful diagnostic tool (SS OCT /SS OCT Anterior image\*<sup>2</sup> / SS OCT Angiography image\*<sup>3</sup> / Color fundus /Red-free /FA / FAF)\*<sup>4</sup> increasing clinical efficiency
- » Direct comparison with fundus images in IMAGEnet 6 Integral\*<sup>3</sup>



Choroid

Courtesy of Srinivas R. Sadda, M.D.,  
Doheny Eye Institute, UCLA

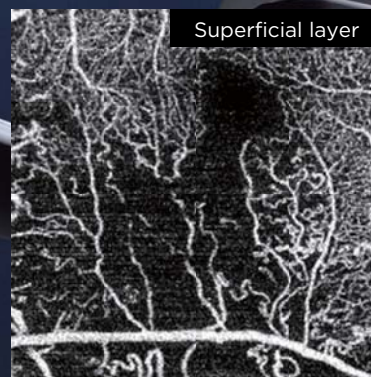
CNV



Choroid

Courtesy of Srinivas R. Sadda, M.D.,  
Doheny Eye Institute, UCLA

GA



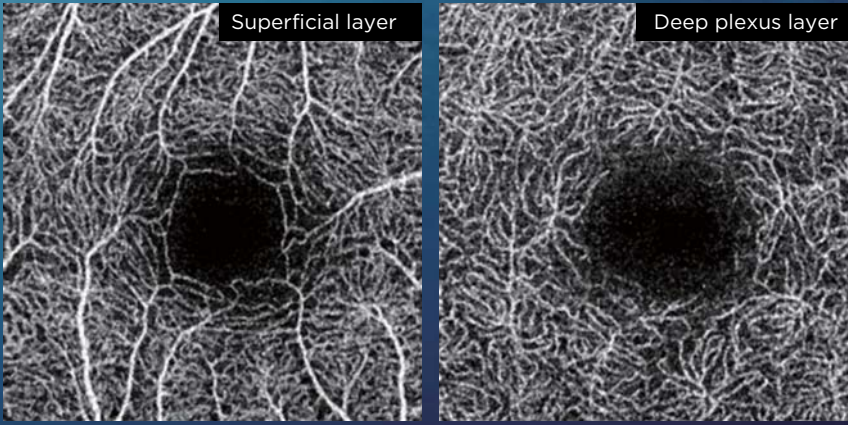
Superficial layer

BRVO

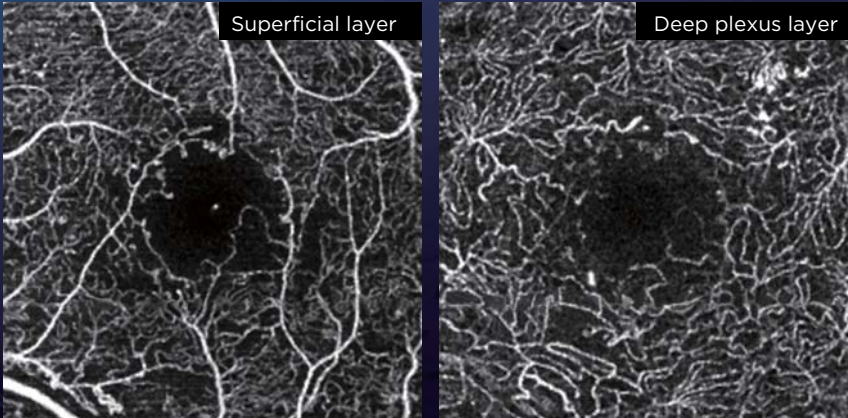
\*<sup>1</sup> Compared to conventional fluorescein angiography  
\*<sup>2</sup> Observation & photography of anterior segment can be performed only when the optional anterior segment attachment kit is used  
\*<sup>3</sup> Optional software  
\*<sup>4</sup> DRI OCT Triton plus : OCT /Anterior OCT (Option)/ OCT Angiography (Option) /Color / Red-Free / FA / FAF  
DRI OCT Triton : OCT /Anterior OCT (Option)/ OCT Angiography (Option) / Color / Red-Free



Image Examples




Normal Eye  
 (Scan: 3.0 x 3.0mm)

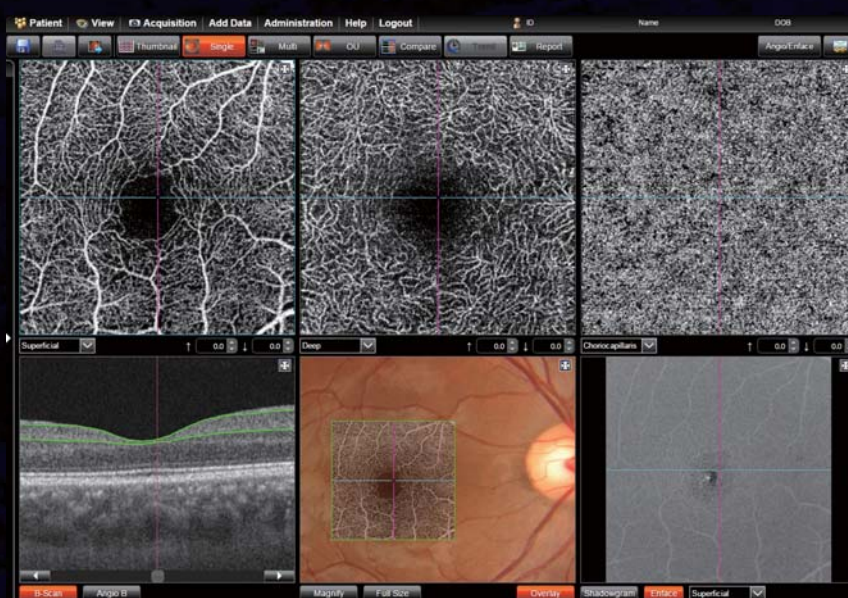


Diabetic Retinopathy  
 (Scan: 3.0 x 3.0mm)

*Courtesy of Dr. A. Ishibazawa and Prof. A. Yoshida  
 (Asahikawa Medical Univ., Japan)*



Glaucoma  
 (Scan: 3.0 x 3.0mm)



Screen image with  
 IMAGEnet 6 Integral  
 (example)

\*OCT Angiography is optional software  
 \*Viewing OCT Angiography image is possible only in combination with IMAGEnet 6 Integral  
 \*Not available for sale in the US